

FEMORAL TRIANGLE

Marc Revol (2010)

BOUNDARIES OF THE TRIANGLE

- Inguinal ligament
- Medial border of the sartorius muscle
- Medial border of the adductor longus muscle

FLOOR OF THE TRIANGLE

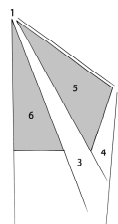
- Medial wall : pectineus and adductor longus
- Lateral wall : iliopsoas and sartorius
- Femoral artery and vein lie anterior to the fascia covering iliopsoas and pectineus muscles
- Femoral nerve lies posterior to the fascia

Superficial vessels

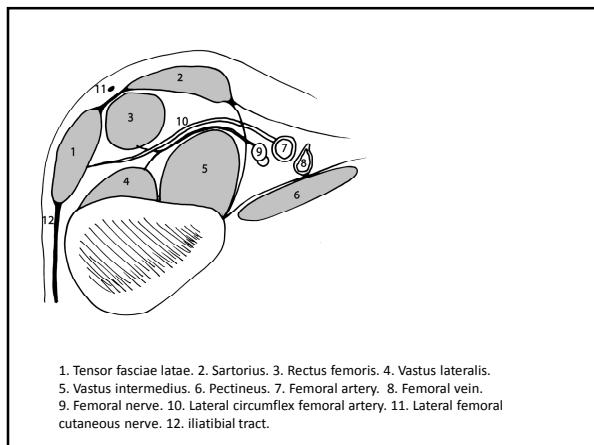
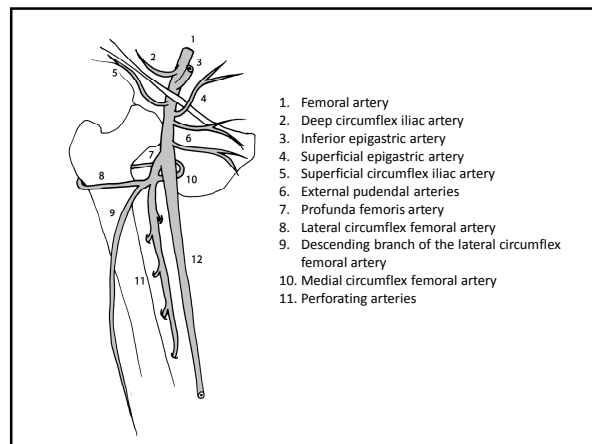
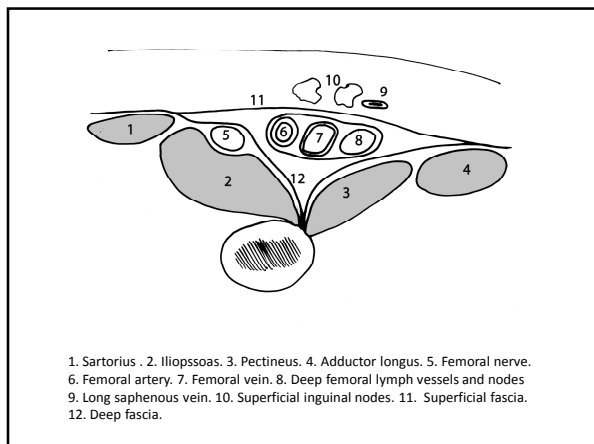
- Arteries are branches of the femoral artery :
 - Superficial circumflex iliac artery
 - Superficial epigastric artery
 - External pudendal arteries
- Veins are tributaries of the great saphenous vein, which passes through the saphenous opening of the superficial fascia

Inguinal lymph nodes

- Superficial nodes :
 - Proximal chain is parallel to the inguinal ligament
 - Distal chain is parallel to the great saphenous vein
- Deep nodes : 2 or 3 nodes on the medial side of the femoral vein



1. Anterior superior iliac spine
2. Pubic tubercle
3. Sartorius
4. Adductor longus
5. Femoral triangle
6. Femoral vein



sources

GRAY'S ANATOMY. The anatomical basis of clinical practice
Elsevier Churchill Livingstone, 39th edition, 2005 (1627 p)

Grant's atlas of anatomy
Williams and Wilkins. Baltimore, 9th edition, 1991 (650 p)

Manuel de chirurgie plastique, reconstructrice et esthétique
Sauramps Médical, 2^{ème} édition, 2009 (874 p)