

GLUTEAL REGION (BUTTOCK)

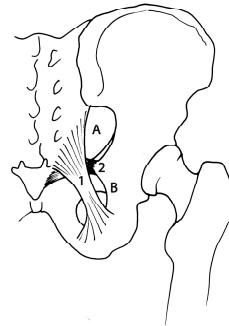
Marc Revol (2010)

MUSCLES

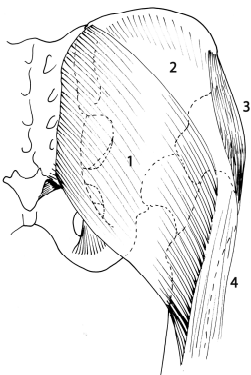
- Gluteus maximus
- Gluteus medius
- Gluteus minimus
- Piriformis
- Obturator internus
- Gemellus inferior and gemellus superior
- Quadratus femoris

VASCULAR SUPPLY & INNERVATION

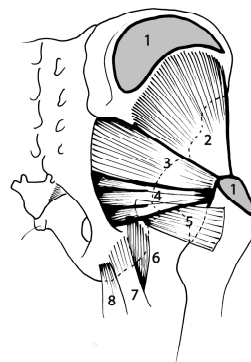
- Above piriformis
 - Superior gluteal artery and veins
 - Superior gluteal nerve
- Below piriformis
 - Inferior gluteal artery and veins
 - Sciatic nerve
 - Nerve to quadratus femoris and gemellus inferior
 - Nerve to obturator and gemellus superior
 - Nerve to piriformis
 - Pudendal nerve
 - Internal pudendal artery
 - Posterior cutaneous nerve of the thigh



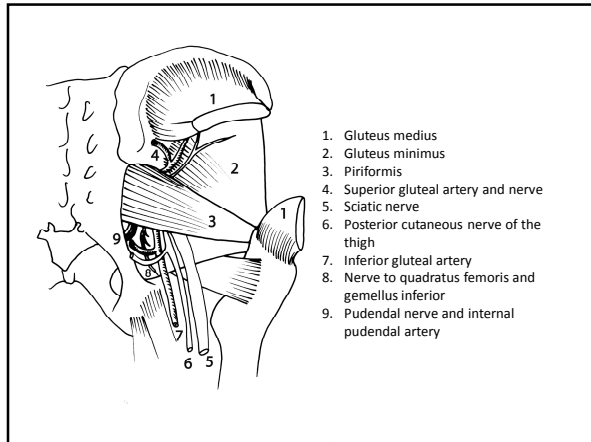
- A. Greater sciatic notch
- B. Lesser sciatic notch
- 1. Sacrotuberous ligament
- 2. Sacrospinous ligament



1. Gluteus maximus
2. Gluteus medius
3. Gluteus minimus
4. Tensor fasciae latae



1. Gluteus medius
2. Gluteus minimus
3. Piriformis
4. Obturator internus and gemelli
5. Quadratus femoris
6. Semimembranosus
7. Biceps (long head)
8. Semitendinosus



SOURCES

GRAY'S ANATOMY. The anatomical basis of clinical practice
Elsevier Churchill Livingstone, 39th edition, 2005 (1627 p)

Manuel de chirurgie plastique, reconstructrice et esthétique
Sauramps Médical, 2^{ème} édition, 2009 (874 p)